

## CLINICAL CASE

Gastroscope  
with single-use  
gastroscope

# ENDOSCOPIC SUBMUCOSAL DISSECTION (ESD) WITH SINGLE-USE GASTROSCOPE

Dr EDUARDO ALBÉNIZ, Dr JUAN J. VILA

Digestive Endoscopy Unit - Navarra University Hospital

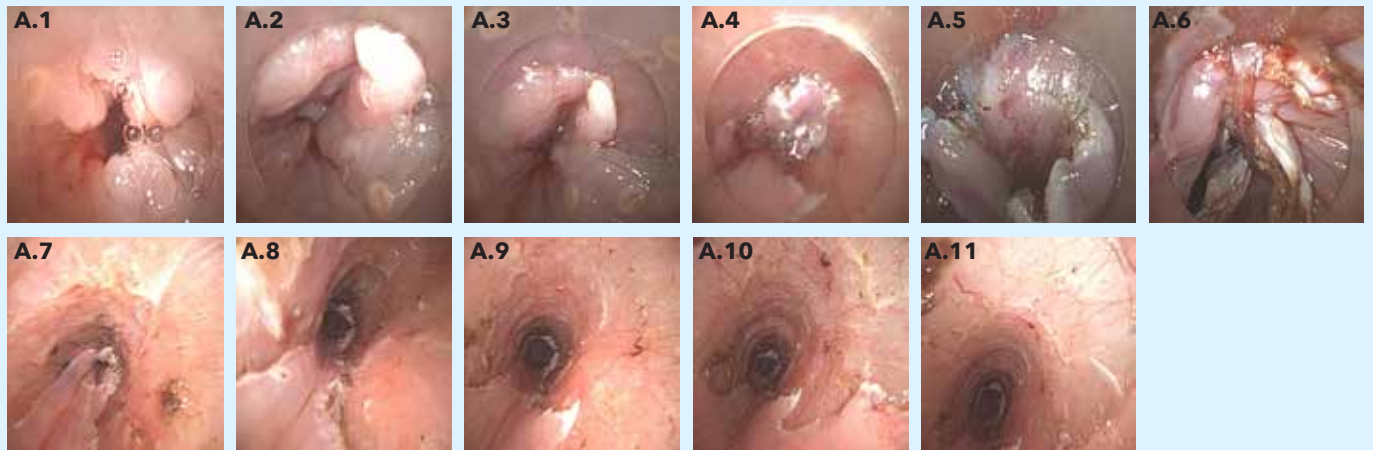
## PATIENT HISTORY

38-year-old woman in right vocal cord squamous carcinoma follow-up. PET-CT shows a hypermetabolic focus at the esophageal-gastric junction. Gastroscope is performed, which reveals, 28 cm along the oesophagus, a raised lesion with a depressed centre and irregular mucosal pattern. A biopsy is taken to target a squamous lesion with high-grade dysplasia/carcinoma in situ. A thoracoabdominal CT scan is performed, showing thickening in the distal oesophagus wall, with no distant dissemination. Endoscopic ultrasound does not detect a clear infiltration of the submucosa. These findings lead to the decision to perform endoscopic submucosal dissection (ESD) using a single-use gastroscope, the Ambu® aScope™ Gastro.

## PROCEDURE

Oesophagus with squamous neoplasia, located 28 cm from the dental arches; has a lengthwise dimension of about 30 mm, morphology (Paris 0IIa, elevated) (Fig. A.1-2) and presents a malignancy pattern with irregular tree-like vessels, some elongated and avascular areas (all suggestive of Sm invasion).

Submucosal dissection is performed using the Ambu aScope Gastro without incident (Fig. A.3-6), obtaining a block piece of 50 x 30 mm, quasi-circumferential eschar by retraction, from 30 cm to 36 cm (Fig. A.7-11). Eschar vessels coagulate. The AP piece is orientated, indicating the oral and anal part.



## CONCLUSION

The histological analysis of the sample shows that it is a 14 mm squamous carcinoma, with ulceration, moderate differentiation with 0.57 mm infiltration of the submucosa, no lymphatic or blood infiltration, no perineural infiltration and with negative margins, with the surgical edge deep at 0.16 mm. The lesion stage is therefore pT1b-sm2.

In this case, the Ambu aScope Gastro allowed the dissection of the described lesion to be performed completely without the need for endoscope exchange. The endoscope's angulation capability is often ideal for submucosal dissection and mucosal resection in difficult-to-access anatomical locations. Therefore, it can greatly facilitate these endoscopic procedures in patients such as this.

# Ambu

Ambu A/S  
Baltorpbakken 13  
2750 Ballerup  
Denmark  
Tel.: +45 7225 2000  
ambu.com